

Ocular Surface Squamous Cell Carcinoma

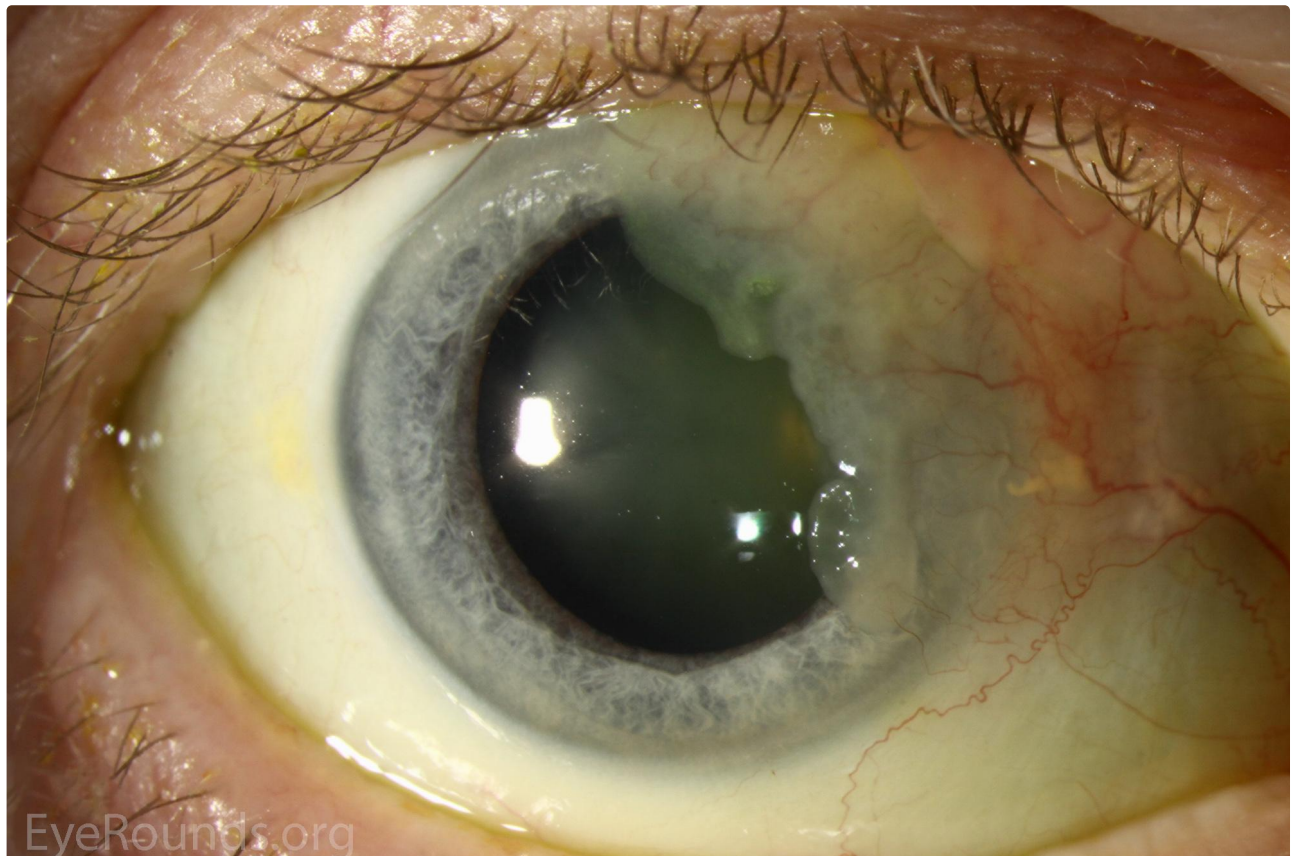
Category(ies): Cornea

Contributor: [William Flanary, MD](#)

Photographer: Carol Chan, CRA



This is an 83-year-old male who presented with an elevated, limbal-based, gelatinous mass. Some adjacent vascular engorgement can be seen. The patient has history of squamous cell carcinoma on the face. Excisional biopsy confirmed the diagnosis of ocular surface squamous cell carcinoma. He subsequently received four months of topical interferon chemotherapy.



 Enlarge

 Download

Image Permissions:



Ophthalmic Atlas Images by [EyeRounds.org](#), [The University of Iowa](#) are licensed under a [Creative Commons Attribution-NonCommercial-NoDerivs 3.0 Unported License](#).

Address

University of Iowa
Roy J. and Lucille A. Carver College
of Medicine
Department of Ophthalmology and
Visual Sciences
200 Hawkins Drive
Iowa City, IA 52242

[Support Us](#)

Legal

Copyright © 2019 The University of
Iowa. All Rights Reserved
[Report an issue with this page](#)
[Web Privacy Policy](#) |
[Nondiscrimination Statement](#)

Related Links

[Cataract Surgery for Greenhorns](#)
[EyeTransillumination](#)
[Gonioscopy.org](#)
[Iowa Glaucoma Curriculum](#)
[Iowa Wet Lab](#)
[Patient Information](#)
[Stone Rounds](#)
[The Best Hits Bookshelf](#)

EyeRounds Social Media

Follow



[Receive notification of new cases,
sign up here](#)
[Contact Us](#)
[Submit a Suggestion](#)